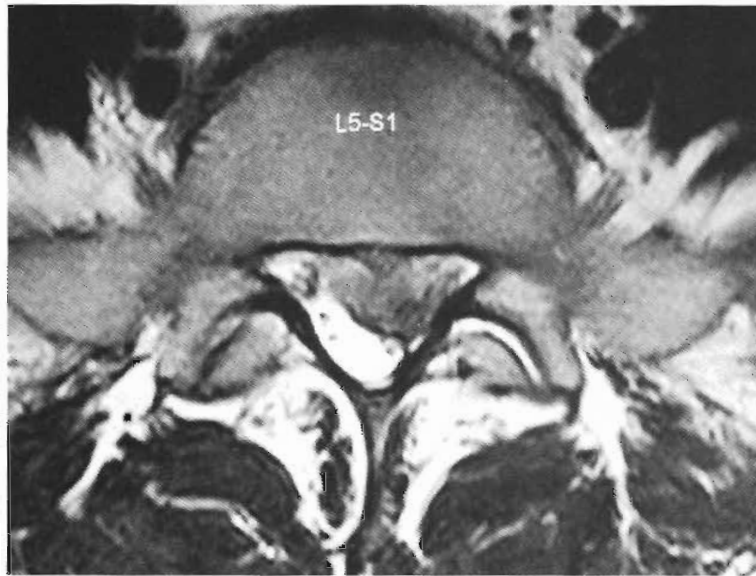
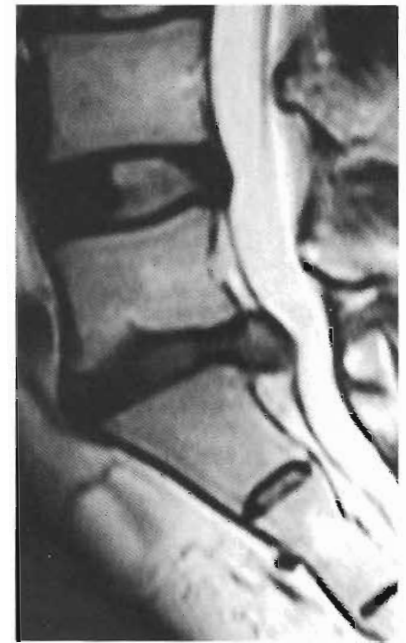
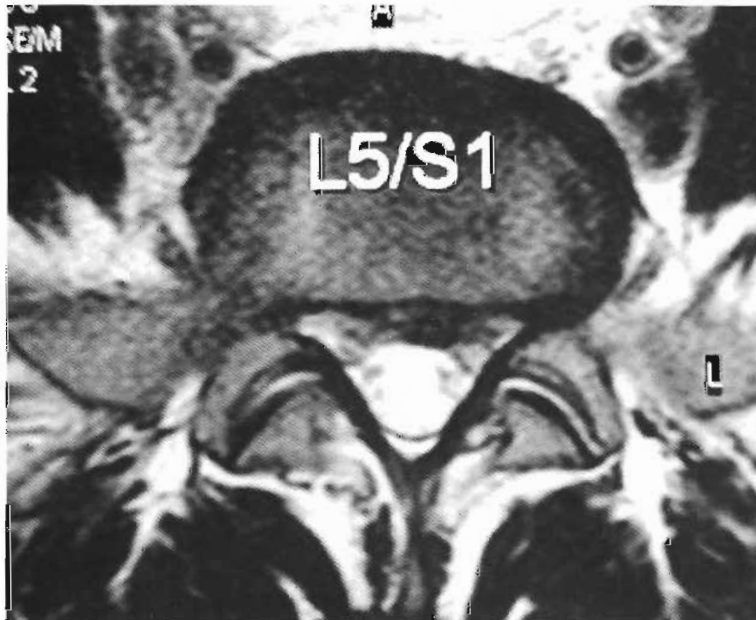A

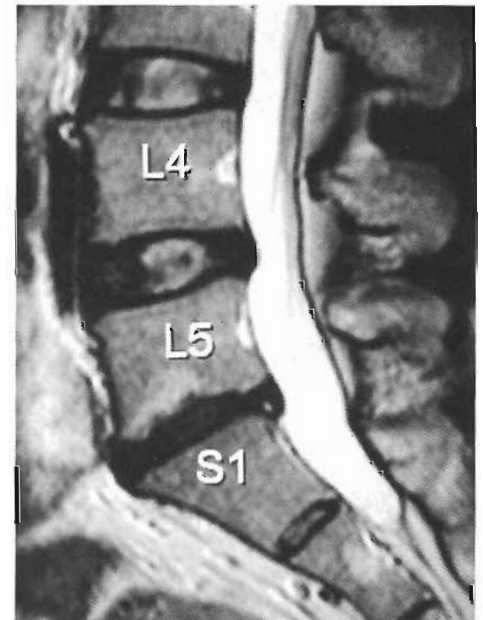


B

Figure 3 T2 weighted MRI image demonstrating a large left paracentral extrusion at L5S1 level.



A



B

Figure 4 T2 weighted MRI image demonstrating near total resolution of disc extrusion.

O₃O₂ injections and physical therapy for three weeks. She became asymptomatic in four weeks and resumed playing daily golf in three months. A follow up MRI scan (figure 4) shows total resolution of disc extrusion. On her last follow-up on 1/15/2005, she remained asymptomatic. She plays an 18 hole round of golf six days a week.

Discussion

Since disc prolapse was first observed by Dandy⁸ and subsequently described in detail by Mixter and Barr⁹ over 70 years ago, its treatment has confounded clinicians and investigators due a relatively high failure rate and complications associated with