

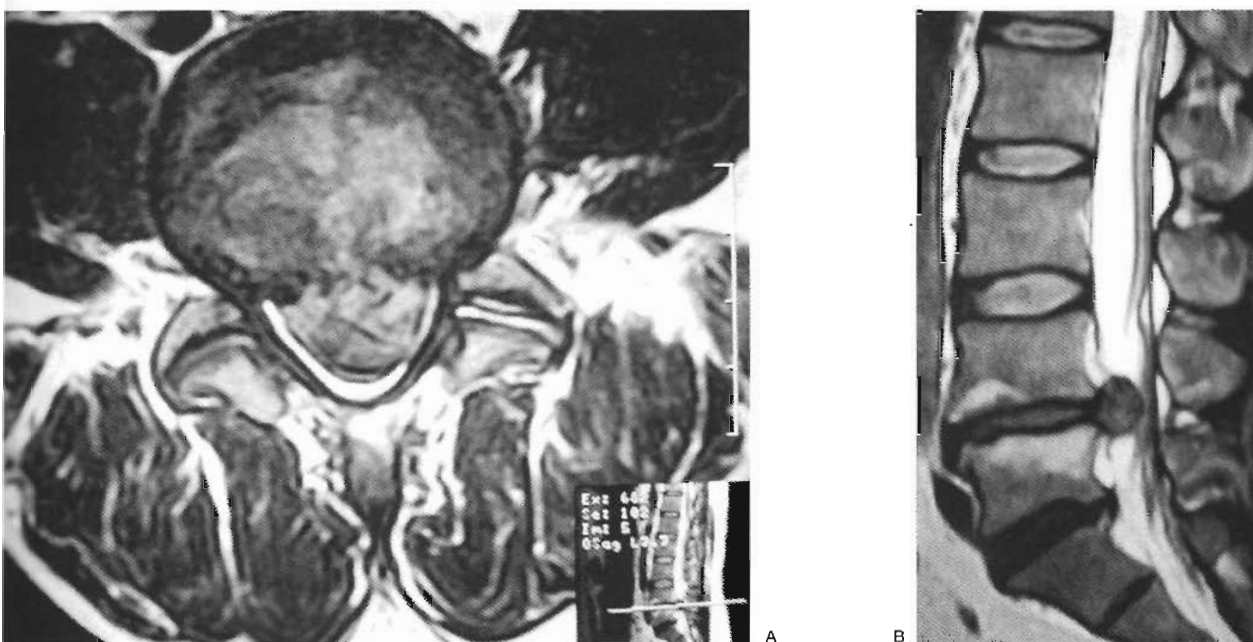Figure 1 T2 weighted MRI image demonstrating a massive L4-5 disc prolapse nearly occupying the entire canal.

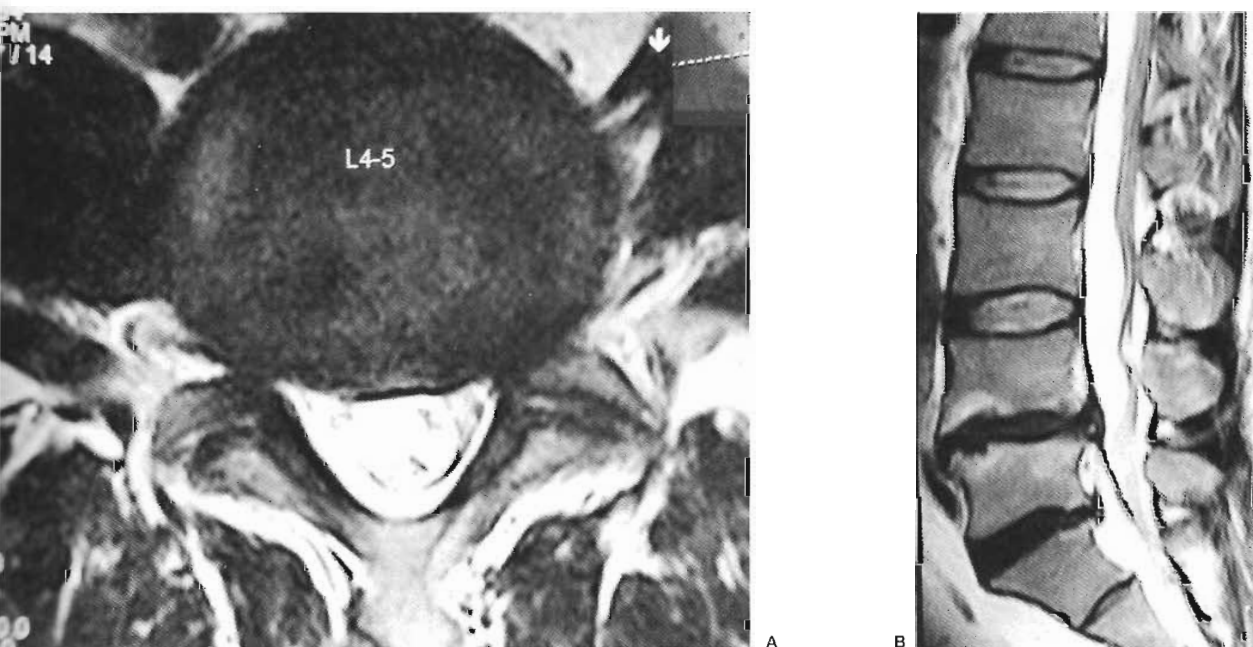


Figure 2 T2 weighted MRI image demonstrating near total resolution of disc prolapse.

had a history of back pain for which an epidural steroid injection had been given five months earlier with a successful outcome. On examination straight leg raising was limited to 30 degrees with absent left ankle reflex and S1 sensory loss. MRI scan (figure 3) showed a large left paracentral protrusion at left L5S1 level.

#### Course

On 6/11/2003, ozonucleolysis (ozone discectomy) was performed using 4 ml intradiscal and 12 ml foraminal  $O_3/O_2$  mixture at a concentration of 29 mcg% under real time fluoroscopic navigation. This was followed by twice weekly IM (pararadicular)